

HIGHLIGHTS OF PRESCRIBING INFORMATION

These highlights do not include all the information needed to use Amyvid safely and effectively. See full prescribing information for Amyvid.

Amyvid (Florbetapir F 18 Injection) for intravenous use

Initial U.S. Approval: 2012

INDICATIONS AND USAGE

Amyvid is a radioactive diagnostic agent for Positron Emission Tomography (PET) imaging of the brain to estimate β -amyloid neuritic plaque density in adult patients with cognitive impairment who are being evaluated for Alzheimer's Disease (AD) and other causes of cognitive decline. A negative Amyvid scan indicates sparse to no neuritic plaques, and is inconsistent with a neuropathological diagnosis of AD at the time of image acquisition; a negative scan result reduces the likelihood that a patient's cognitive impairment is due to AD. A positive Amyvid scan indicates moderate to frequent amyloid neuritic plaques; neuropathological examination has shown this amount of amyloid neuritic plaque is present in patients with AD, but may also be present in patients with other types of neurologic conditions as well as older people with normal cognition. Amyvid is an adjunct to other diagnostic evaluations (1).

Limitations of Use

- A positive Amyvid scan does not establish a diagnosis of AD or other cognitive disorder (1).
- Safety and effectiveness of Amyvid have not been established for:
 - Predicting development of dementia or other neurologic condition;
 - Monitoring responses to therapies (1).

DOSAGE AND ADMINISTRATION

Use appropriate radiation safety handling measures (2.1).

- Administer 370 MBq (10 mCi) as a single intravenous bolus in a total volume of 10 mL or less (2.2).

- Obtain 10-minute PET images starting approximately 30 to 50 minutes after intravenous injection (2.3).
- Image interpretation: Refer to full prescribing information (2.4).
- The radiation absorbed dose from a 370 MBq (10 mCi) dose of Amyvid is 7 mSv in an adult (2.5).

DOSAGE FORMS AND STRENGTHS

10 mL, 30 mL, or 50 mL multidose vial containing a clear, colorless injectable solution at a strength of 500-1900 MBq/mL (13.5-51 mCi/mL) florbetapir F 18 at End of Synthesis (EOS) (3).

CONTRAINDICATIONS

None (4).

WARNINGS AND PRECAUTIONS

- Image interpretation errors (especially false negatives) have been observed (5.1).
- Radiation risk: Amyvid, similar to all radiopharmaceuticals, contributes to a patient's long-term cumulative radiation exposure. Ensure safe handling to protect patients and health care workers from unintentional radiation exposure (2.1, 5.2).

ADVERSE REACTIONS

The most common reported adverse reaction was headache, occurring in 2% of patients, followed by musculoskeletal pain, blood pressure increased, fatigue, nausea, and injection site reaction, all occurring in <1% of patients (6).

To report SUSPECTED ADVERSE REACTIONS, contact Eli Lilly and Company at 1-800-LillyRx (1-800-545-5979) or FDA at 1-800-FDA-1088 or www.fda.gov/medwatch

See 17 for PATIENT COUNSELING INFORMATION

Revised: 12/2013

FULL PRESCRIBING INFORMATION: CONTENTS***1 INDICATIONS AND USAGE****2 DOSAGE AND ADMINISTRATION**

- 2.1 Radiation Safety - Drug Handling
- 2.2 Recommended Dosing and Administration Instructions
- 2.3 Image Acquisition Guidelines
- 2.4 Image Display and Interpretation
- 2.5 Radiation Dosimetry

3 DOSAGE FORMS AND STRENGTHS**4 CONTRAINDICATIONS****5 WARNINGS AND PRECAUTIONS**

- 5.1 Risk for Image Misinterpretation and other Errors
- 5.2 Radiation Risk

6 ADVERSE REACTIONS

- 6.1 Clinical Trials Experience

7 DRUG INTERACTIONS**8 USE IN SPECIFIC POPULATIONS**

- 8.1 Pregnancy
- 8.3 Nursing Mothers
- 8.4 Pediatric Use
- 8.5 Geriatric Use

11 DESCRIPTION

- 11.1 Physical Characteristics
- 11.2 External Radiation

12 CLINICAL PHARMACOLOGY

- 12.1 Mechanism of Action
- 12.2 Pharmacodynamics
- 12.3 Pharmacokinetics

13 NONCLINICAL TOXICOLOGY

- 13.1 Carcinogenesis, Mutagenesis, Impairment of Fertility

14 CLINICAL STUDIES**16 HOW SUPPLIED/STORAGE AND HANDLING**

- 16.1 How Supplied
- 16.2 Storage and Handling

17 PATIENT COUNSELING INFORMATION

* Sections or subsections omitted from the full prescribing information are not listed

FULL PRESCRIBING INFORMATION**1 INDICATIONS AND USAGE**

Amyvid is indicated for Positron Emission Tomography (PET) imaging of the brain to estimate β -amyloid neuritic plaque density in adult patients with cognitive impairment who are being evaluated for Alzheimer's Disease (AD) and other causes of cognitive decline. A negative Amyvid scan indicates sparse to no neuritic plaques and is inconsistent with a neuropathological diagnosis of AD at the time of image acquisition; a negative scan result reduces the likelihood that a patient's cognitive impairment is due to AD. A positive Amyvid scan indicates moderate to frequent amyloid neuritic plaques; neuropathological examination has shown this amount of amyloid neuritic plaque is present in patients with AD, but may also be present in patients with other types of neurologic conditions as well as older people with normal cognition. Amyvid is an adjunct to other diagnostic evaluations.

Limitations of Use:

- A positive Amyvid scan does not establish a diagnosis of AD or other cognitive disorder.
- Safety and effectiveness of Amyvid have not been established for:
 - Predicting development of dementia or other neurologic condition;
 - Monitoring responses to therapies.

2 DOSAGE AND ADMINISTRATION

2.1 Radiation Safety - Drug Handling

Amyvid is a radioactive drug and should be handled with appropriate safety measures to minimize radiation exposure during administration [see *Warnings and Precautions (5.1)*]. Use waterproof gloves and effective shielding, including syringe shields when handling Amyvid. Radiopharmaceuticals, including Amyvid, should only be used by or under the control of physicians who are qualified by specific training and experience in the safe use and handling of radioactive materials, and whose experience and training have been approved by the appropriate governmental agency authorized to license the use of radiopharmaceuticals.

2.2 Recommended Dosing and Administration Instructions

The recommended dose for Amyvid is 370 MBq (10 mCi), maximum 50 µg mass dose, administered as a single intravenous bolus in a total volume of 10 mL or less. Follow the injection with an intravenous flush of 0.9% sterile sodium chloride.

- Inspect the radiopharmaceutical dose solution prior to administration and do not use it if it contains particulate matter or is discolored.
- Use aseptic technique and radiation shielding to withdraw Amyvid solution.
- Assay the dose in a suitable dose calibrator prior to administration.
- Inject Amyvid through a short intravenous catheter (approximately 1.5 inches or less) to minimize the potential for adsorption of the drug to the catheter. Portions of the Amyvid dose may adhere to longer catheters.

2.3 Image Acquisition Guidelines

A 10-minute PET image should be acquired starting 30 to 50 minutes after Amyvid intravenous injection. The patient should be supine and the head positioned to center the brain, including the cerebellum, in the PET scanner field of view. Reducing head movement with tape or other flexible head restraints may be employed. Image reconstruction should include attenuation correction with resulting transaxial pixel sizes between 2 and 3 mm.

2.4 Image Display and Interpretation

Amyvid images should be interpreted only by readers who successfully complete a special training program [see *Warnings and Precautions (5.1)*]. Training is provided by the manufacturer using either an in-person tutorial or an electronic process.

The objective of Amyvid image interpretation is to provide an estimate of the brain β -amyloid neuritic plaque density, not to make a clinical diagnosis. Image interpretation is performed independently of a patient's clinical features and relies upon the recognition of unique image features.

Image Display

Images should be displayed in the transaxial orientation with access as needed to the sagittal and coronal planes. In reviewing the images, include all transaxial slices of the brain using a black-white scale with the maximum intensity of the scale set to the maximum intensity of all the brain pixels. Initially locate the brain slice with the highest levels of image contrast (highest radioactivity signals for Amyvid uptake) and adjust the contrast appropriately. Start image interpretation by displaying slices sequentially from the bottom of the brain to the top. Periodically refer to the sagittal and coronal plane image display, as needed to better define the radioactivity uptake and to ensure that the entire brain is displayed.

Image Interpretation

Image interpretation is based upon the distribution of radioactive signal within the brain; clinical information is not a component of the image assessment [see *Warnings and Precautions (5.1)*]. Images are designated as positive or negative by comparing the radioactivity in cortical gray matter with activity in the adjacent white matter. This determination is made only in the cerebral cortex; the signal uptake in the cerebellum does not contribute to the scan interpretation (for example, a positive scan may show retained cerebellar gray-white contrast even when the cortical gray-white contrast is lost).

- *Negative scans* show more radioactivity in white matter than in gray matter, creating clear gray-white contrast.
- *Positive scans* show cortical areas with reduction or loss of the normally distinct gray-white contrast. These scans have one or more areas with increased cortical gray matter signal which results in reduced (or absent) gray-white contrast. Specifically, a positive scan will have either:
 - a) Two or more brain areas (each larger than a single cortical gyrus) in which there is reduced or absent gray-white contrast. This is the most common appearance of a positive scan.
 - or
 - b) One or more areas in which gray matter radioactivity is intense and clearly exceeds radioactivity in adjacent white matter.

Some scans may be difficult to interpret due to image noise, atrophy with a thinned cortical ribbon, or image blur. For cases in which there is uncertainty as to the location or edge of gray matter on the PET scan and a co-registered computerized tomography (CT) image is available (as when the study is done on a PET/CT scanner) the interpreter should examine the CT image to clarify the relationship of the PET radioactivity and the gray matter anatomy.

Figures 1, 2, and 3 provide examples of negative and positive scans. Figure 1 demonstrates varying degrees of normal gray-white contrast (negative) and examples where gray-white contrast has been lost (positive). Figure 2 illustrates typical features of a negative scan, while Figure 3 shows the loss of gray-white contrast in different brain regions of a positive scan.

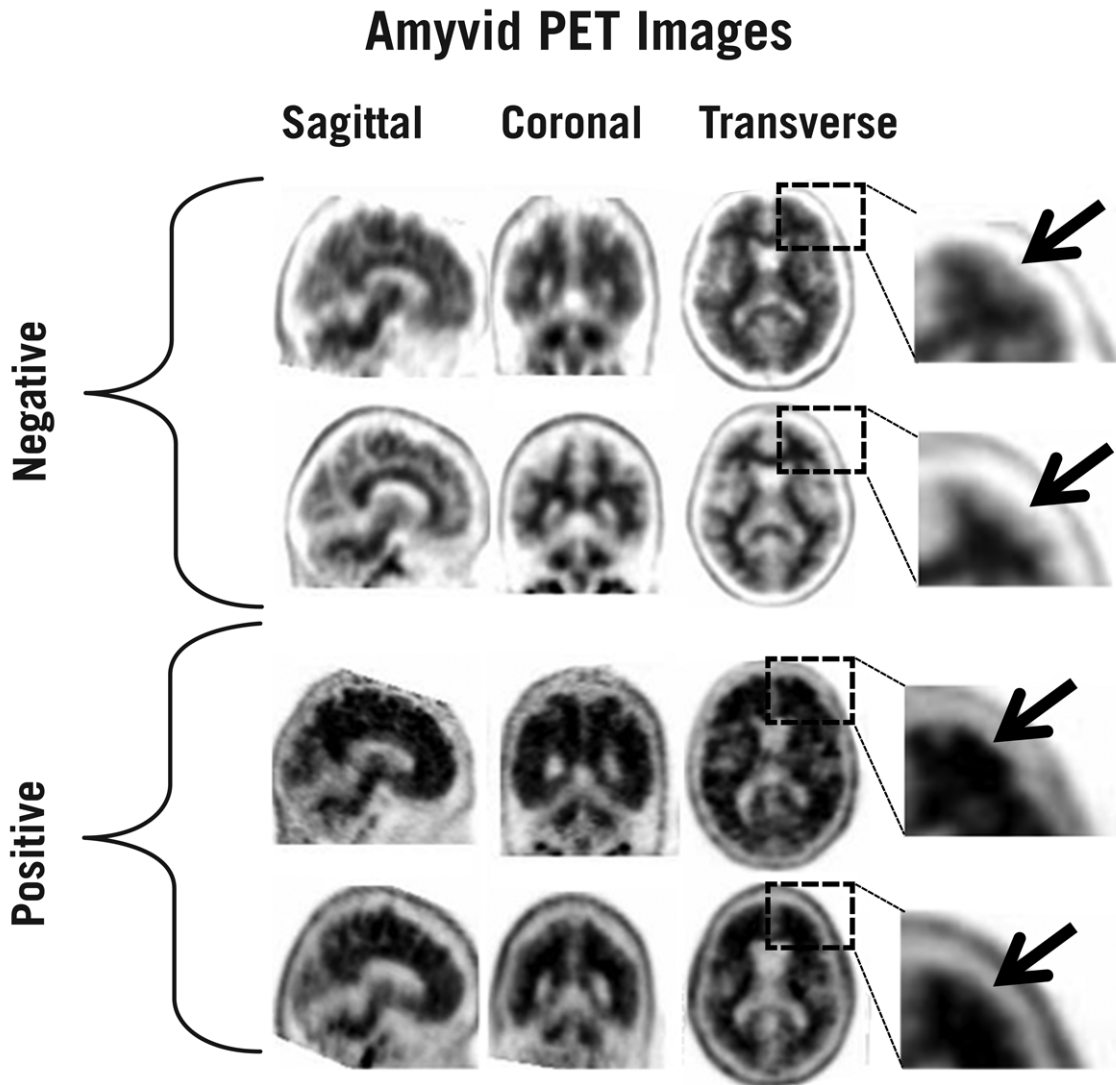


Figure 1: Examples of Amyvid negative scans (top two rows) and positive scans (bottom two rows). Left to right panels show sagittal, coronal, and transverse PET image slices. Final panel to right shows enlarged picture of the brain area under the box. The top two arrows are pointing to normal preserved gray-white contrast with the cortical radioactivity less than the adjacent white matter. The bottom two arrows indicate areas of decreased gray-white contrast with increased cortical radioactivity that is comparable to the radioactivity in the adjacent white matter.

Negative

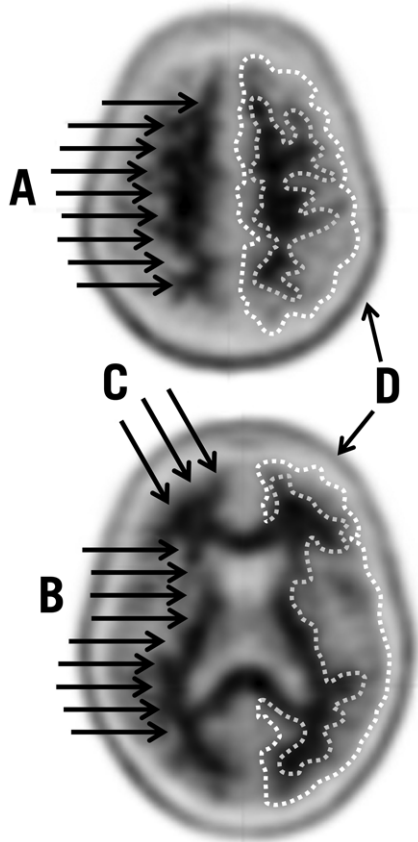


Figure 2: Typical Negative Scan. Images are displayed from a negative scan with upper (top) and lower (bottom) transverse slices both showing good gray-white matter contrast. On the right side of each slice, dotted lines have been used to illustrate the edge of the cortical gray matter (outer line) and the gray-white border (inner line). These dotted lines highlight contrast in uptake between the less intense uptake in the gray matter and the more intense uptake in the white matter. In addition, arrows illustrate the following points:

- A) White matter tracts can be delineated from the frontal lobe to parietal lobe.
- B) White matter tracts are clearly identified throughout the occipital / temporal area.
- C) Scalloped appearance is seen with “fingers” of white matter in the frontal cortex.
- D) Low levels of tracer in scalp or skull that should be distinguished from gray matter uptake by its shape and position.

Positive

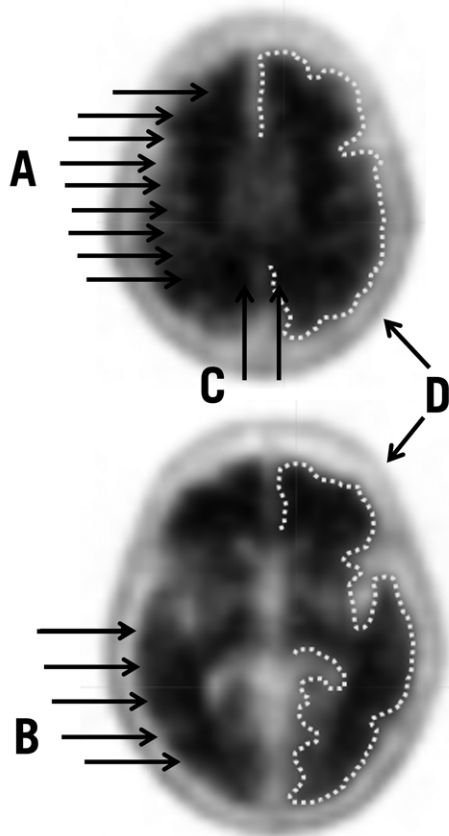


Figure 3: Typical Positive Scan: Images from a positive scan showing upper (top) and lower (bottom) transverse slices with loss of gray-white matter contrast in multiple brain regions. On the right side of each slice the edge of the cortical gray matter has been illustrated with a dotted line. Compared to the images from the negative case in Figure 2, the gray matter uptake is more similar to the white matter uptake and the gray-white matter border is more difficult to discern. In addition, arrows show the following points:

- A) White matter tracts are difficult to fully identify as they travel from frontal to parietal lobe.
- B) Borders of white matter tracts in occipital / temporal area are lost in places.
- C) Gray matter in medial parietal cortex (precuneus) has increased uptake.
- D) Low levels of tracer in scalp or skull that should be distinguished from gray matter uptake by its shape and position.

2.5 Radiation Dosimetry

The estimated radiation absorbed doses for adults from intravenous injection of Amyvid are shown in Table 1.

Table 1: Estimated Radiation Absorbed Dose, Amyvid (Florbetapir F 18 Injection)

ORGAN/TISSUE	MEAN ABSORBED DOSE PER UNIT ADMINISTERED ACTIVITY($\mu\text{Gy}/\text{MBq}$)
Adrenal	14
Bone - Osteogenic Cells	28
Bone - Red Marrow	14
Brain	10
Breasts	6
Gallbladder Wall	143
GI ^a - Lower Large Intestine Wall	28
GI - Small Intestine	66
GI - Stomach Wall	12
GI - Upper Large Intestine Wall	74
Heart Wall	13
Kidneys	14
Liver	64
Lungs	9
Muscle	9
Ovaries	18
Pancreas	14
Skin	6
Spleen	9
Testes	7
Thymus	7
Thyroid	7
Urinary Bladder Wall	27
Uterus	16
Total Body	12
Effective Dose ($\mu\text{Sv}/\text{MBq}$) ^b	19

^a Gastrointestinal

^b Assumed radiation weighting factor, w_r , (formerly defined as quality factor, Q) of 1 for conversion of absorbed dose (Gray or rads) to dose equivalent (Sieverts or rem) for F 18. To obtain radiation absorbed dose in rad/mCi from above table, multiply the dose in $\mu\text{Gy}/\text{MBq}$ by 0.0037, (e.g., $14 \mu\text{Gy}/\text{MBq} \times 0.0037 = 0.0518 \text{ rad}/\text{mCi}$)

The effective dose resulting from a 370 MBq (10 mCi) dose of Amyvid is 7.0 mSv in an adult, ($19 \times 370 = 7030 \mu\text{Sv} = 7.030 \text{ mSv}$). The use of a CT scan to calculate attenuation correction for reconstruction of Amyvid images (as done in PET/CT imaging) will add radiation exposure. Diagnostic head CT scans using helical scanners administer an average of $2.2 \pm 1.3 \text{ mSv}$ effective dose (CRCPD Publication E-07-2, 2007). The actual radiation dose is operator and scanner dependent. The total radiation exposure from Amyvid administration and subsequent scan on a PET/CT scanner is estimated to be 9 mSv.

3 DOSAGE FORMS AND STRENGTHS

Amyvid (Florbetapir F 18 Injection) is available in a 10 mL, 30 mL, and 50 mL multidose vial containing a clear, colorless solution at a strength of 500-1900 MBq/mL (13.5-51 mCi/mL) florbetapir F 18 at End of Synthesis (EOS).

4 CONTRAINDICATIONS

None

5 WARNINGS AND PRECAUTIONS

5.1 Risk for Image Misinterpretation and other Errors

Errors may occur in the Amyvid estimation of brain neuritic plaque density during image interpretation [see *Clinical Studies (14)*].

Image interpretation should be performed independently of the patient's clinical information. The use of clinical information in the interpretation of Amyvid images has not been evaluated and may lead to errors. Other errors may be due to extensive brain atrophy that limits the ability to distinguish gray and white matter on the Amyvid scan as well as motion artifacts that distort the image.

Amyvid scan results are indicative of the brain neuritic amyloid plaque content only at the time of image acquisition and a negative scan result does not preclude the development of brain amyloid in the future.

5.2 Radiation Risk

Amyvid, similar to other radiopharmaceuticals, contributes to a patient's overall long-term cumulative radiation exposure. Long-term cumulative radiation exposure is associated with an increased risk of cancer. Ensure safe handling to protect patients and health care workers from unintentional radiation exposure [see *Dosage and Administration (2.1)*].

6 ADVERSE REACTIONS

6.1 Clinical Trials Experience

Because clinical trials are conducted under widely varying conditions, adverse reaction rates observed in the clinical trials of a drug cannot be directly compared to rates in the clinical trials of another drug and may not reflect the rates observed in clinical practice.

In clinical studies, 555 patients were exposed to Amyvid. Amyvid caused no serious adverse reactions in the studies and the reported adverse reactions were predominantly mild to moderate in severity. The adverse reactions reported in more than one subject within the studies are shown in Table 2.

Table 2: Adverse Reactions Reported in Clinical Trials (N=555 patients)

Adverse Reactions	N (Percent of patients)
Headache	10 (1.8%)
Musculoskeletal pain	4 (0.7%)
Blood pressure increased ^a	4 (0.7%)
Nausea	4 (0.7%)
Fatigue	3 (0.5%)
Injection site reaction ^b	3 (0.5%)
Anxiety	2 (0.4%)
Back pain	2 (0.4%)
Claustrophobia	2 (0.4%)
Dizziness	2 (0.4%)
Feeling cold ^c	2 (0.4%)
Insomnia	2 (0.4%)
Neck pain	2 (0.4%)

^a Includes the terms blood pressure increased and hypertension.

^b Includes the terms injection site haemorrhage, injection site irritation, and injection site pain.

^c Includes the terms feeling cold and chills.

Other adverse reactions occurred at lower frequencies and included infusion site rash, dysgeusia, pruritis, urticaria, and flushing.

7 DRUG INTERACTIONS

Pharmacodynamic drug-drug interaction studies have not been performed in patients to establish the extent, if any, to which concomitant medications may alter Amyvid image results.

Within a clinical study of patients with a range of cognitive impairment, some patients with probable AD were receiving the following medications: donepezil, galantamine, memantine. Mean cortical Standardized Uptake Value (SUV) ratios did not differ between the patients taking or not taking these concomitant medications. In *in vitro* tests, none of the drugs tested, including the acetylcholinesterase inhibitors donepezil, galantamine, and tacrine, altered florbetapir F 18 binding to its target.

8 USE IN SPECIFIC POPULATIONS

8.1 Pregnancy

Pregnancy Category C. It is not known whether Amyvid can affect reproductive capacity or cause fetal harm when administered to a pregnant woman. Animal reproduction studies have not been conducted with Amyvid. Amyvid should be administered to a pregnant woman only if clearly needed.

All radiopharmaceuticals, including Amyvid, have a potential to cause fetal harm. The likelihood of fetal harm depends on the stage of fetal development and the magnitude of the radiopharmaceutical dose. Assess pregnancy status before administering Amyvid to a female of reproductive potential.

8.3 Nursing Mothers

It is not known whether Amyvid is excreted in human milk. Because many drugs are excreted into human milk and because of the potential for radiation exposure to nursing infants from Amyvid, avoid use of the drug in a breastfeeding mother or have the mother temporarily interrupt breastfeeding for 24 hours (>10 half-lives of radioactive decay for the F 18 isotope) after exposure to Amyvid. If breastfeeding is interrupted, the patient should pump and discard her breast milk and use alternate infant nutrition sources (e.g., stored breast milk or infant formula) for 24 hours after administration of the drug.

8.4 Pediatric Use

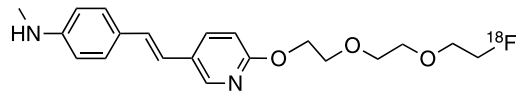
Amyvid is not indicated for use in pediatric patients.

8.5 Geriatric Use

Of 496 patients in completed clinical studies of Amyvid, 307 patients were ≥ 65 years old (203 patients were over 75 years of age). No overall differences in safety or effectiveness were observed between these subjects and younger subjects.

11 DESCRIPTION

Amyvid contains florbetapir F 18, a molecular imaging agent that binds to β -amyloid aggregates, and is intended for use with PET imaging of the brain. Chemically, florbetapir F 18 is described as (E)-4-(2-(6-(2-(2-(2-[^{18}F] fluoroethoxy)ethoxy)ethoxy)pyridine-3-yl)vinyl)-N-methylbenzamine. The molecular weight is 359 and the structural formula is:



Amyvid is a sterile, non-pyrogenic radioactive diagnostic agent for intravenous injection. The clear, colorless solution is supplied ready to use and each milliliter contains 0.1 to 19 micrograms of florbetapir and 500 - 1900 MBq (13.5 - 51 mCi) florbetapir F 18 at EOS, 4.5 mg sodium ascorbate USP and 0.1 mL dehydrated alcohol USP in 0.9% sodium chloride injection USP. The pH of the solution is between 5.5 and 7.5.

11.1 Physical Characteristics

Amyvid is radiolabeled with [^{18}F] fluorine (F 18) that decays by positron (β^+) emission to O 18 and has a half-life of 109.77 minutes. The principal photons useful for diagnostic imaging are the coincident pair of 511 keV gamma photons, resulting from the interaction of the emitted positron with an electron (Table 3).

Table 3: Principal Radiation Produced from Decay of Fluorine 18

Radiation	Energy Level (keV)	Abundance (%)
Positron	249.8	96.9
Gamma	511	193.5

11.2 External Radiation

The point source air-kerma coefficient^a for F-18 is 3.74E -17 Gy m²/(Bq s); this coefficient was formerly defined as the specific gamma-ray constant of 5.7 R/hr/mCi at 1 cm. The first half-value thickness of lead (Pb) for F 18 gamma rays is approximately 6 mm^b. The relative reduction of radiation emitted by F-18 that results from various thicknesses of lead shielding is shown in Table 4. The use of ~8 cm of Pb will decrease the radiation transmission (i.e., exposure) by a factor of about 10,000.

Table 4: Radiation Attenuation of 511 keV Gamma Rays by Lead Shielding

Shield Thickness cm of lead (Pb)	Coefficient of Attenuation
0.6	0.5
2	0.1
4	0.01
6	0.001
8	0.0001

^a Eckerman KF and A Endo. MIRD: Radionuclide Data and Decay Schemes, 2nd Edition, 2008.

^b Derived from data in NCRP Report No. 49. 1998, Appendix C

12 CLINICAL PHARMACOLOGY

12.1 Mechanism of Action

Florbetapir F 18 binds to β -amyloid plaques and the F 18 isotope produces a positron signal that is detected by a PET scanner. In *in vitro* binding studies using postmortem human brain homogenates containing β -amyloid plaques, the dissociation constant (K_d) for florbetapir was 3.7 ± 0.3 nM. The binding of florbetapir F 18 to β -amyloid aggregates was demonstrated in postmortem human brain sections using autoradiographic methods, thioflavin S and traditional silver staining correlation studies as well as monoclonal antibody β -amyloid-specific correlation studies. Florbetapir binding to tau protein and a battery of neuroreceptors was not detected in *in vitro* studies.

12.2 Pharmacodynamics

Following intravenous injection, florbetapir F 18 diffuses across the human blood-brain barrier and produces a radioactivity signal detectable throughout the brain. Subsequently, cerebral perfusion decreases the brain florbetapir F 18 content, with differential retention of the drug in areas that contain β -amyloid aggregates compared to areas that lack the aggregates. The time-activity curves for florbetapir F 18 in the brain of subjects with positive scans show continual signal increases from time zero through 30 minutes post-administration, with stable values thereafter up to at least 90 minutes post-injection. Differences in the signal intensity between portions of the brain that specifically retain florbetapir F 18 and the portions of the brain with nonspecific retention of the drug forms the image interpretation methods [see *Dosage and Administration (2.4)*].

Clinical studies evaluated the test-retest distribution of florbetapir F 18 within the brains of 21 subjects (11 with probable AD and 10 healthy volunteers) who underwent two injections (with PET scans), separated by a time period of 2 to 30 days. Images were shown to maintain signal distribution reproducibility when evaluated qualitatively (by a reader masked to image time points) as well as quantitatively using an automated assessment of SUV in pre-specified brain regions. A comparison of a 10-minute image acquisition time versus a 20-minute acquisition time showed no difference in the mean cortical to cerebellar SUV ratio results obtained.

12.3 Pharmacokinetics

Following the intravenous administration of 370 MBq (10 mCi) of florbetapir F 18 to healthy volunteers, the drug was distributed throughout the body with less than 5% of the injected F 18 radioactivity present in the blood by 20 minutes following administration, and less than 2% present by 45 minutes after administration. The residual F 18 in circulation during the 30-90 minute imaging window was principally in the form of polar F 18 metabolites. Whole body scanning following the intravenous injection showed accumulation of radioactivity in the liver within four minutes post-injection, followed by elimination of the radioactivity predominantly through the biliary/gastrointestinal tract with much lower radioactivity detected in the bladder. Essentially all radioactivity collected in the urine was present as polar metabolites of florbetapir F 18.

13 NONCLINICAL TOXICOLOGY

13.1 Carcinogenesis, Mutagenesis, Impairment of Fertility

Animal studies to assess the carcinogenicity or reproductive toxicity potentials of Amyvid have not been conducted.

In an *in vitro* bacterial reverse mutation assay (Ames test), increases in the number of revertant colonies were observed in 2 of the 5 strains exposed to ^{19}F -AV-45, the non-radioactive form of florbetapir F 18. In a chromosomal aberration *in vitro* study with cultured human peripheral lymphocytes, ^{19}F -AV-45 did not increase the percentage of cells with structural aberrations with 3-hour exposure with or without activation; however, 22-hour exposure produced a statistically significant increase in structural aberrations at all tested concentrations. Potential *in vivo* genotoxicity of ^{19}F -AV-45 was evaluated in a rat micronucleus study. In this assay, ^{19}F -AV-45 did not increase the number of micronucleated polychromatic erythrocytes at the highest achievable dose level, 372 $\mu\text{g}/\text{kg}/\text{day}$, when given twice daily for 3 consecutive days.

14 CLINICAL STUDIES

Amyvid was evaluated in three clinical studies that examined images from healthy adult subjects as well as subjects with a range of cognitive disorders, including some terminally ill patients who had agreed to participate in a postmortem brain donation program. All the studies were single arm studies in which subjects underwent an Amyvid injection and scan and then had images interpreted by multiple independent readers who were masked to all clinical information. Image interpretations used co-registration with CT scans when PET scans were performed on dual PET-CT scanners.

In Study One, a semi-quantitative Amyvid image interpretation method, which is not intended for clinical use, was used by three readers to interpret images from 152 terminally ill patients, of whom 35 underwent autopsy (29 included in primary analysis). The median patient age was 85 years (range 55 to 103 years) and 14 of the patients were female. Eighteen of the patients had dementia, 9 had no cognitive impairment and 2 had mild cognitive impairment (MCI). The main study outcome was a comparison of premortem Amyvid images to the findings from a postmortem brain examination (truth standard). The semi-quantitative measures consisted of a five-point whole brain Amyvid uptake image scoring outcome that was compared to a global score of the percentage of the whole brain that contained amyloid, as determined by immunohistochemical microscopy. The percentage of postmortem cortical amyloid burden ranged from 0 to 9% and correlated with the median Amyvid scores (Spearman's $\rho=0.78$; $p<0.0001$, 95% CI, 0.58 to 0.89).

Studies Two and Three used a clinically-applicable binary image interpretation method (positive/negative) to evaluate images from a range of patients who had participated in earlier studies. The studies assessed performance characteristics (sensitivity and specificity) among subjects with a postmortem amyloid neuritic plaque density truth standard. Additionally, inter-reader and intra-reader image interpretation reproducibility was assessed among all the subjects, including subjects who lacked a postmortem truth standard. Before image interpretation, all readers underwent special training: Study Two used an in-person tutoring type of training and Study Three used an electronic media-based training method. Five trained readers interpreted images independently within each study. The brain neuritic plaque density in both studies was determined using an algorithm in which microscopic measures of highest plaque density within a brain region were averaged to produce a global brain estimate of neuritic plaque density. The global neuritic plaque density was categorized in the same manner as that for a region (Table 5),

where plaques were counted on slides with modified Bielschowsky silver stained tissue sections. For purposes of determining the agreement between the in-vivo Amyvid image results and the post-mortem whole brain amyloid neuritic plaque density, Amyvid results (negative/positive) were pre-specified to correspond with specific plaque density scores, based upon a modification of the Consortium to Establish a Registry for Alzheimer's Disease (CERAD) criteria which use neuritic plaque counts as a necessary pathological feature of AD.

Table 5: Global and Regional Neuritic Plaque Density^a Correlates to Amyvid Image Results

Neuritic Plaque Counts	CERAD Score	Amyvid Image Result
<1	none	Negative
1 - 5	sparse	
6 - 19	moderate	Positive
20+	frequent	

^a J of Neuropathology and Experimental Neurology 1997; 56(10):1095.

Study Two examined images only from terminally ill patients who had premortem Amyvid scans and postmortem brain examinations to determine a truth standard. Among the 59 patients, 35 of whom were also in Study One, the median age was 83 years (range 47 to 103 years), half were females and most were Caucasian (93%). Twenty-nine patients had an AD clinical diagnosis, 13 had another type of dementing disorder, 12 had no history of cognitive impairment and 5 had MCI. The time interval between the Amyvid scan and death was less than one year for 46 patients and between one and two years for 13 patients. Among the subset of patients who died within one year of Amyvid scanning (a prespecified outcome), the sensitivity using the majority interpretation of the readers was 96% (95% CI: 80% to 100%) and specificity was 100% (95% CI: 78% to 100%). With the entire dataset of 59 patients, the sensitivity using the majority interpretation of the readers was 92% (95% CI: 78% to 98%) and specificity was 100% (95% CI: 80% to 100%). At autopsy, the global brain neuritic plaque density category (CERAD score, as in Table 5) was: frequent n=30; moderate n=9; sparse n=5; and none n=15. Tables 6 and 7 show the Amyvid performance characteristics among all the patients. Among the subset of patients who died within one year of Amyvid scanning (n=46; 28 positive and 18 negative based on histopathology) the median (and range) of correct read results, false negatives, and false positives were 44 (37 to 45), 1 (0 to 7), and 1 (0 to 2), respectively, for In-Person Training (Study Two); and were 43 (38 to 44), 3 (0 to 7), and 1 (0 to 2), respectively, for Electronic Media Training (Study Three).

Table 6: Amyvid Scan Results by Reader Training Method among Autopsied Patients (n = 59)

Test Performance		In-Person Training (Study Two)	Electronic Media Training (Study Three)
Sensitivity (%)	Median	92	82
	Range among the 5 readers	(69 – 95)	(69 – 92)
Specificity (%)	Median	95	95
	Range among the 5 readers	(90 – 100)	(90 – 95)

Table 7: Amyvid Correct and Erroneous Scan Results by Reader Training Method among Autopsied Patients

Read Result		In-Person Training (Study Two)					Electronic Media Training (Study Three)				
		Reader					Reader				
		1	2	3	4	5	6	7	8	9	10
All Scans with Autopsies (N=59^a)	Correct	55	56	53	56	45	49	54	46	53	51
	False Negative	3	2	5	3	12	8	3	12	5	7
	False Positive	1	1	1	0	2	2	2	1	1	1

^a 39 positive and 20 negative based on histopathology

Study Three included images from subjects who did not have a truth standard (20 healthy volunteers, 52 patients with mild cognitive impairment, 20 patients with AD) as well as all 59 of the patients who underwent an autopsy (same patients as in Study Two) and provided a truth standard. Duplicate images of 33 patients were included within the total pool of images in order to assess intra-reader image reproducibility. Among the 151 subjects, the median age was 76 years (range 47 to 103), half were females and most were Caucasian (93.4%). Performance characteristics for patients with a truth standard are shown above (Tables 6 and 7). The major reproducibility results are shown in Table 8 for various groups of subjects. Inter-reader reproducibility analyses for all images showed an overall Fleiss' kappa statistic of 0.83 (95% CI: 0.78 to 0.88); the lower bound of the 95% CI exceeded the pre-specified success criterion (95% CI lower bound >0.58). Intra-reader reproducibility analyses showed that, between the two readings for each of the 33 patients with duplicate images, one of the five readers had complete

agreement for all 33 patients, two readers had discrepant reads for a single patient, one reader had discrepant reads for two patients and another reader had discrepant reads for three patients.

Table 8: Number of Positive Amyvid Scan Results within Study Three Subject Groups and Reproducibility of Scan Results Among Readers

Subject group by cognitive and truth standard (TS, autopsy) status	Positive Scans, n ^a	Kappa (95% CI)	Percent of Scans with Inter-reader Agreement		
			3 of 5 readers agree	4 of 5 readers agree	5 of 5 readers agree
All subjects with a TS, n=59	33	0.75 (0.67, 0.83)	14	10	76
All subjects without a TS, n=92	33	0.88 (0.82, 0.94)	2	11	87
AD, n=49 (29 with TS; 20 no TS)	38	0.67 (0.58, 0.76)	10	14	76
MCI, n=57 (5 with TS; 52 no TS)	17	0.91 (0.83, 0.99)	2	7	91
Cognitively normal without TS, n=20	4	0.83 (0.69, 0.97)	5	5	90
Cognitively normal with TS, n=12	1	0.73 (0.55, 0.87)	0	8	92
Other (non-AD) dementia with TS, n=13	7	0.52 (0.35, 0.69)	23	23	54

^a Shown is the median number of scans interpreted as positive across the 5 readers for each subgroup of patients listed in the first column.

16 HOW SUPPLIED/STORAGE AND HANDLING

16.1 How Supplied

Amyvid is supplied in 10 mL, 30 mL, or 50 mL vials containing 10 mL, 10-30 mL, or 10-50 mL, respectively, of a clear, colorless solution at a strength of 500 - 1900 MBq/mL (13.5 - 51 mCi/mL) florbetapir F 18 at EOS. Each vial contains multiple doses and is enclosed in a shielded container to minimize external radiation exposure.

10 mL	NDC 0002-1200-10 (IC1200)
30 mL	NDC 0002-1200-30 (IC1200)
50 mL	NDC 0002-1200-50 (IC1200)

16.2 Storage and Handling

Store Amyvid at 25°C (77°F); excursions permitted to 15°C to 30°C (59°F to 86°F) [see USP Controlled Room Temperature]. The product does not contain a preservative. Store Amyvid within the original container or equivalent radiation shielding. Amyvid must not be diluted.

This preparation is approved for use by persons under license by the Nuclear Regulatory Commission or the relevant regulatory authority of an Agreement State.

17 PATIENT COUNSELING INFORMATION

- Instruct patients to inform their physician or healthcare provider if they are pregnant or breastfeeding.
- Inform patients who are breastfeeding to use alternate infant nutrition sources (e.g., stored breast milk or infant formula) for 24 hours (>10 half-lives of radioactive decay for the F 18 isotope) after administration of the drug or avoid use of the drug.

Marketed by Lilly USA, LLC, Indianapolis, IN 46285, USA

Copyright © 2012, 2013, Eli Lilly and Company. All rights reserved.